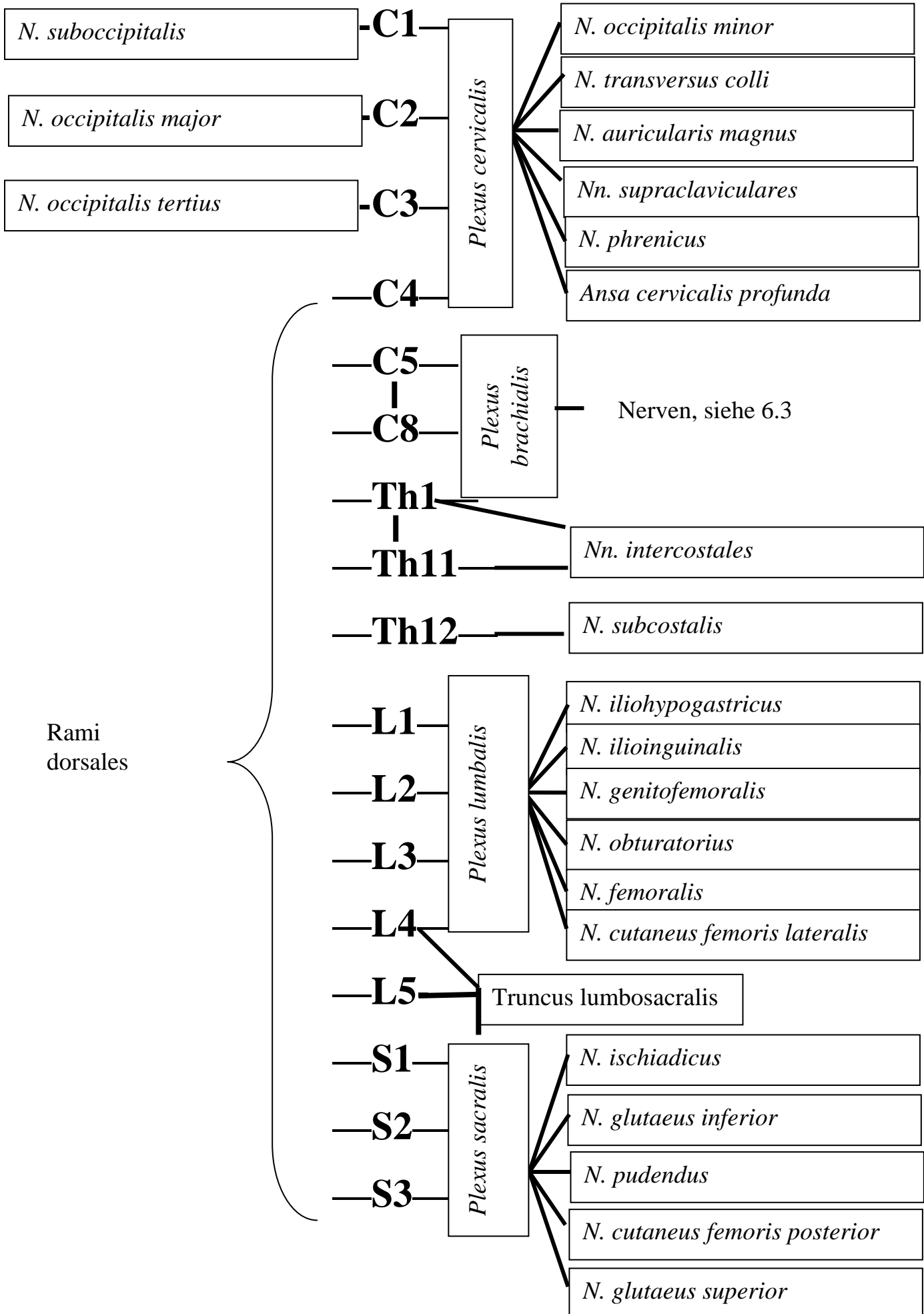


**Seminar 8+**  
**8.2**

Rami dorsales

Rami ventrales



## 8.2 Zusatzfrage Antwort: Hirnnerven, sensible Ganglien

### 8.4

#### Pars supraclavicularis

1. *N. dorsalis scapulae*
2. *N. thoracicus longus*
3. *N. thoracodorsalis*
4. *N. suprascapularis*
5. *N. subscapularis*
6. *Nn. pectorales*
7. *N. subclavius*

#### Pars infraclavicularis

1. *N. musculocutaneus*
2. *N. medianus*
3. *N. ulnaris*
4. *N. axillaris*
5. *N. radialis*
6. *N. cutaneus brachii medialis*
7. *N. cutaneus antibrachii medialis*